

---

**SHORT COMMUNICATION**

---

---

# Incomplete extrusion of an acrylic punctum plug in a case of severe dry eye syndrome

F. FASCE, R. BRANCATO

Department of Ophthalmology and Visual Sciences, University Hospital San Raffaele, Milan - Italy

---

**PURPOSE.** *To report a case of extrusion of a new soft punctum plug with thermoexpansion property (Medennium SmartPLUG).*

**METHODS.** *A soft punctum plug was implanted in a 32-year-old woman with a severe dry eye syndrome in juvenile arthritis.*

**RESULTS.** *One week after implant the plug partially extruded outside the punctum. Despite this adverse event, all subjective dry eye symptoms increased.*

**CONCLUSION.** *The peculiarity of this case is the persistence of clinical efficacy of the soft punctum plug even if partially extruded. The patient experienced relief of symptoms that can be compared to the benefits usually obtained with a successfully implanted silicon plug. (Eur J Ophthalmol 2005; : 000)*

**KEY WORDS.** *Punctum plug, Dry eye*

*Accepted: August 3, 2004*

---

## INTRODUCTION

Severe dry eye is one of the more frequent sources of visual disability. Punctal occlusion was shown to be an effective method to extend the persistence of lacrimal fluid, both natural and supplemental, in the eye requiring supplement lubrication (1, 2). The decision concerning the choice of one among the different lacrimal plugs to implant in dry eye patients is primarily influenced by the personal experience of the clinician. Other factors that may influence this choice are the design of the plug, principally the external profile and size, the mechanical properties of the plug, the flexibility of the material, and reversibility of the implant. The ideal plug should be safe and comfortable.

Since the availability of the canalicular plugs, one of the major problems of the punctal plugs was determining correct size of the plug and falling out of the implants. Fitting silicone plugs can be resolved in the majority of cases by improving the size of the plug whenever the previous has been extruded. As for comfort, the low profile head of the newer plugs does not poke the conjunctiva or the cornea.

New types of punctum plugs entered the market in recent years, but the most innovative concept comes from the use of soft molding material.

The Medennium SmartPLUG is a new hydrophobic acrylic punctal occlusion devised with a thermoexpansion property. Before insertion, at temperature less than 30°, the SmartPLUG is a rigid rod, easy to handle and to insert without the use of any injector or

---

---

dilator. At body temperature it contracts in length and expands in diameter to conform to the shape of the punctum.

## Case report

A 32-year-old woman with a severe dry eye syndrome in juvenile arthritis presented to the dry eye service of our department complaining of increasing floaters and blurred vision for 6 months.

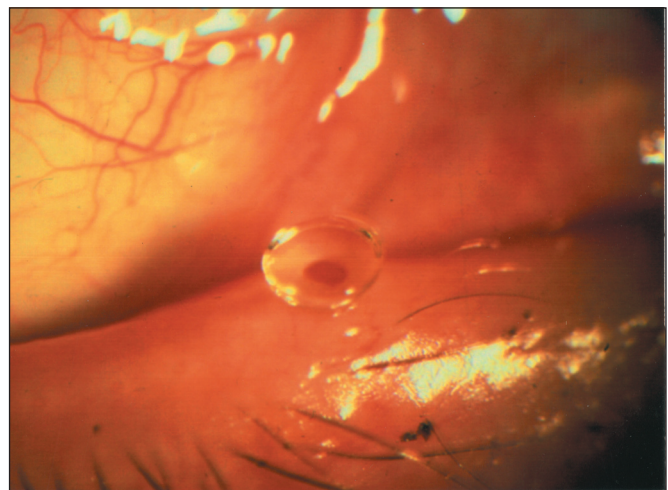
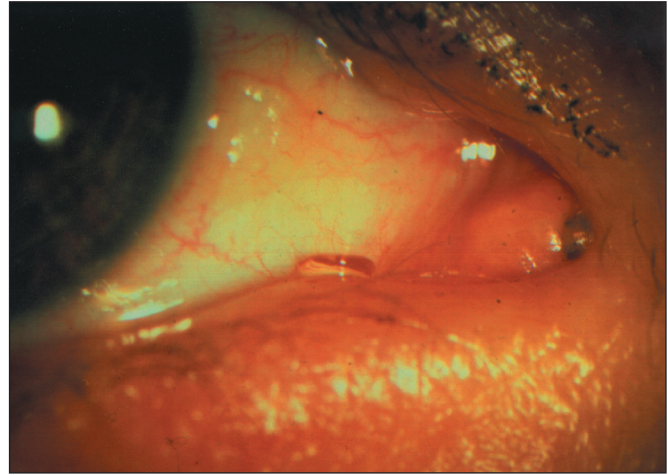
The slit lamp examination demonstrated a severe fluorescein and rose bengal staining of the ocular surface. The Schirmer test was less than 2 mm in 5', the break-up time was less than 5 sec. The best-corrected visual acuity (BCVA) ranged from 0.6 to 0.8 depending on the wetting status of corneal surface.

The patient failed the use of contact lenses for severe discomfort in the last 2 years. The decision to insert the punctum plugs came from the necessity to fit, at least for a few hours a day, the contact lenses. This was necessary for the patient's career as an abdominal surgeon.

We decided to insert a Medennium SmartPLUG. The technique of handling and inserting the plug was the one recommended by Medennium. To remove the plug from the carrier we used the Push Rod by Medennium. We used a McPherson forceps to grasp the Smart Plug instead of the Forceps Model 502 from Medennium. We were careful to avoid exercising any excessive pressure in grasping the smart plug to avoid damage to the surface of the plug.

A single drop of artificial tear and lidocaine 1% was instilled less than 1 minute before the plug insertion. Three-fourths of the plug was inserted to the lower lid punctal with a McPherson forceps exercising, with a finger, a slight depression to the lower lid to evert the lacrimal punctum. The depression of the lower lid was interrupted when the last portion of the plug apparently disappeared in the vertical portion of the lower canaliculus.

One week post plugs insertion the patient reported an improvement of dry eye symptoms and a reduction of frequency of lubricant use. At the same time the patient noted the presence of the plug partially extruded outside the punctum. At slit lamp observation, in the left eye, the last portion of the plug was extruded outside the punctum not associated with local hyperemia or limbus staining (Fig.1). The extrud-



**Fig. 1** - Clinical appearance of the partial extrusion of the punctum plug (a), lacrimal punctum everted with the lower lid depression (b).

ed portion of the plug was removed with a Vanna's scissors and the remaining portion of the plug entered inside the canaliculus.

The patient attended a second visit 1 week later. All dry eye symptoms—ocular pain, redness, burning, and blurred vision—increased permanently.

## DISCUSSION

The use of punctal plugs is a successful, simple, and reversible procedure in most patients with severe dry eye (4). **AQ: Please cite Ref. 3 in text**

laura sartori  
AQ: Is it correct, or is decreased  
meant here?